

Narrow-Diameter Implant versus Lateral Bone Augmentation: What are the Evidences?

Moustapha Saad – Msc, FICOI

Msc. Periodontology, private practice TYR- Lebanon, French Dental Center Abu Dhabi UAE and Tamim dental clinic, Doha – Qatar
moustapha_saad@yahoo.fr

André Assaf – Associate Professor

Clinical Associate Professor, Department of Prosthodontics, Faculty of Dentistry, Beirut Arab University. Former Head of Fixed Prosthodontics department, Lebanese University, President of the Lebanese Society of Prosthodontics, Beirut – Lebanon

ABSTRACT

For optimizing functional and esthetic implant therapy results, sufficient bone amount is required at the reception site. A reduced buccolingual ridge dimension may not allow the placement of a standard-diameter implant without the risk of implant thread exposure. In such situations, lateral bone augmentation procedures can be performed that would allow a restorative-driven placement of standard-diameter implants. Conversely, the use of narrow-diameter implants (diameter $\leq 3.5\text{mm}$) could be another predictable solution to avoid any invasive surgical management. The aim of this review is to analyze the survival rate of narrow-diameter implants as well as the effectiveness of different techniques for lateral bone augmentation in improving implant clinical outcomes.

KEYWORDS

Narrow-diameter implants, Lateral bone augmentation, Survival rates.

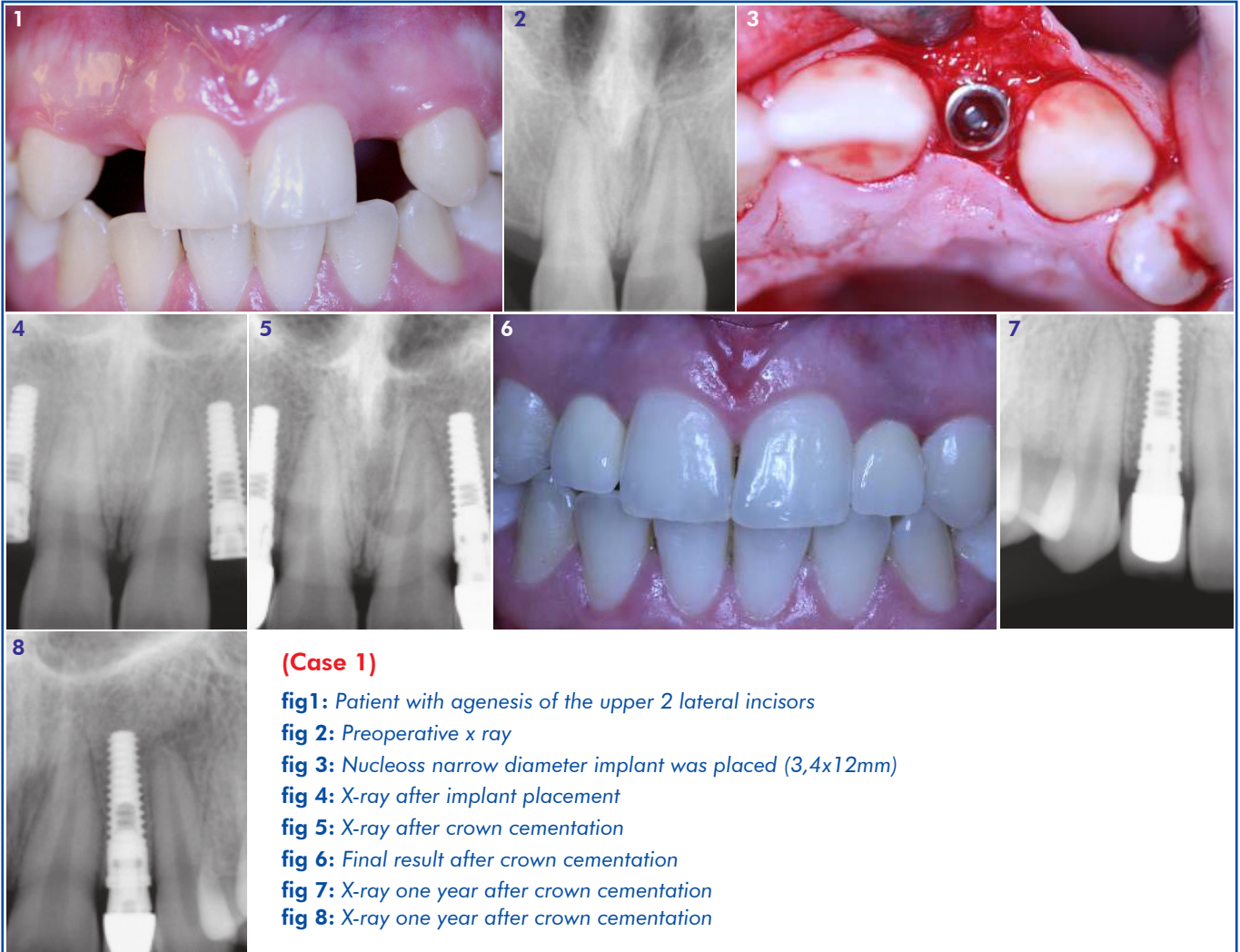
INTRODUCTION

For an optimal implant therapy, a minimum amount of bone width and height are required at the recipient site. That will provide a functional and cosmetic implant borne restoration. Unfortunately, the resorption of the alveolar ridges may render the placement of standard-diameter implants difficult or impossible. In these cases, two options are available; 1) place a standard-diameter implant after performing a reconstructive surgery to recreate the correct bone volume and morphology, or 2) simply use a narrow-diameter implant. (Chiapasco *et al.* 2006, 2009, 2012).

A number of surgical procedures have been used for creating adequate bone width. In extreme horizontal bone resorption, the procedure is best performed before implant placement and is followed by a period for healing (two stage/staged approach). It can also be combined with the implant placement (one stage/simultaneous approach). Regardless of the chosen protocol, it involves bone grafting with different types of grafts (autografts, allografts, xenografts, bone substitutes), Guided Bone Regeneration (GBR) alone or in combination with grafting procedures, as well as the use of ridge expansion techniques utilizing "split" ridge osteotomy. In parallel, autogenous bone grafts continue to be used for the reconstruction of partial and full edentulism with various degrees of success (Jensen and Sindet-Pedersen 1991; Pikos 2005; Blanco *et al.* 2005, Khoury 2007; Esposito *et al.* 2008).

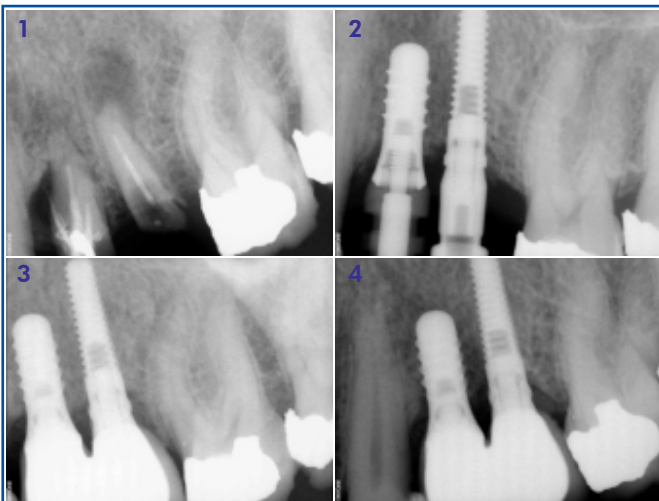In the recent years, several articles have reported data on the use of small-diameter implants not only in the frontal areas (Polizzi *et al.* 1999; Andersen *et al.* 2001; Cordaro *et al.* 2006), but also in the posterior partially edentulous jaws and in totally edentulous patients (Polizzi *et al.* 1999; Davarpanah *et al.* 2000; Vigolo *et al.* 2004; Romeo *et al.* 2006; Froum *et al.* 2007; Degidi *et al.* 2008; Morneburg and Pröschel 2008; Veltri *et al.* 2008). Complications are expected to be more than those generally observed for the standard-diameter implant, namely implant fracture, abutment fracture (Quek *et al.* 2006; Album *et al.* 2008; Flanagan 2008), screw loosening or fracture and ceramic fracture. To reduce these risks, innovations in implants material and components (implant's macro and microgeometry, platform switching etc.) were recently introduced, making of the use of narrow-diameter implant in all kind of edentulism a serious consideration.

Regardless of the chosen modality, whether with narrow-diameter implants or lateral bone augmentation with wider implants, one of the essential requirements for success is the predictability of the procedure. The aim of the debate is therefore to evaluate the effectiveness of narrow-diameter implants and of lateral ridge augmentation to allow the placement of standard- or wide-diameter implants in the treatment of horizontally resorbed jaws. A literature review is performed to answer a main question: Is the survival rate of narrow-diameter implant comparable to standard-diameter implants placed in lateral bone augmentation?



(Case 1)

- fig 1:** Patient with agenesia of the upper 2 lateral incisors
- fig 2:** Preoperative x ray
- fig 3:** Nucleoss narrow diameter implant was placed (3,4x12mm)
- fig 4:** X-ray after implant placement
- fig 5:** X-ray after crown cementation
- fig 6:** Final result after crown cementation
- fig 7:** X-ray one year after crown cementation
- fig 8:** X-ray one year after crown cementation



(Case 2)

- fig 1:** Preoperative x-ray, showing hopeless upper 2; 1st and 2nd premolar
- fig 2:** X-ray during pick-up impression 3 months after implant placement (1 Straumann standard diameter implant 4.1x10mm was placed to replace the first premolar and one Nucleoss narrow diameter implant 3.4x12mm to replace the 2nd premolar)
- fig 3:** X-ray after crown cementation
- fig 4:** X-ray 12 months after cementation. Note the excellent bone level on both, standard diameter and narrow diameter implant

SURVIVAL & SUCCESS RATE OF NARROW-DIAMETER IMPLANTS

Since 1990, studies have reported a high percentage of success for narrow-diameter implants. Indeed, the available Brånemark implants used before that period of implant dentistry had a diameter of 3.5mm and were placed mainly in the area of lower incisors and upper lateral incisors. (Adel *et al.* 1990).

Romeo *et al.* (2006), Olate *et al.* (2010), Vigolo *et al.* and Buser *et al.* (1997) showed an elevated success rate using small-diameter implants, similar to standard-diameter implants. They also demonstrated that implant success is not related to the implant diameter. Renouard and Nisand (2006) concluded that the reported bone loss figures around narrow implant were within the ranges found around standard-diameter implant.

In a prospective pilot study with 2 years follow-up, Barter et al used narrow-diameter implants (3.3mm made of titanium zirconium alloy) splinted to standard- or wide-diameter implants in all kinds of partial edentulism. For all diameters, success rate, marginal bone resorption and changes in peri-implant soft tissues were recorded. Minor guided bone regeneration procedures were allowed at time of implant surgery to cover fenestrations or dehiscences less than 2mm. Concerning the narrow-diameter implants; **1)** their use was restricted to positions between the central incisor and 2nd premolar, **2)** the overall success rate was 95.2%, **3)** the changes in bone levels were less than 1mm, with a probing depth ranging from 1.43-1.95 at loading to 2.21-2.89 after loading.

Romeo et al. (2006) in a longitudinal retrospective study evaluated the success rate of narrow-diameter implant, compared to standard-diameter implant excluding bone graft or local GBR procedures before implant placement (TPS surface, 10 and 12mm of length). The cumulative success rate was in the maxilla 96.1% and 96.8% and in the mandible 92% and 97.9% respectively. The mean marginal bone resorption was not statistically different.

Chiapasco et al. (2012) and El-Nawas et al. (2011) have shown that narrow-diameter implants used alone could be a reliable treatment for posterior jaw or for full mouth rehabilitation.

For Arisan et al. (2010), the posterior localization of narrow-diameter implant would increase the risk of late term complications and failure as well as the marginal bone resorption. No implant fractures were reported. In their study, 139 patients received 316 narrow-diameter implant (3.3mm and 3.4mm) placed in different location of the jaw (anterior-posterior) with a follow up between 5-10 years. The overall cumulative survival rate was 92.3% and the success rate 91.4%.

In the study of Zinsli et al. (2004) with 149 partially or totally edentulous patients having received 298 implants, a cumulative survival rate of 98.7% of narrow implants (3.3mm diameter) was reported after 5 years. The implant restoration was either fixed (single crown, fixed partial, complete fixed prosthesis) or removable (overdenture).

Málo et al. (2011) showed that the implant system and the occlusal scheme would affect the narrow implant survival rates.

SURVIVAL & SUCCESS RATE OF IMPLANTS PLACED IN HORIZONTALLY GRAFTED SITES

There is a wide range of complexity in lateral ridge augmentation procedures. They can vary from simple procedures for coverage of dehiscences or fenestrations, to more complicated techniques using onlay bone blocks prior to implant placement. When analyzing success,

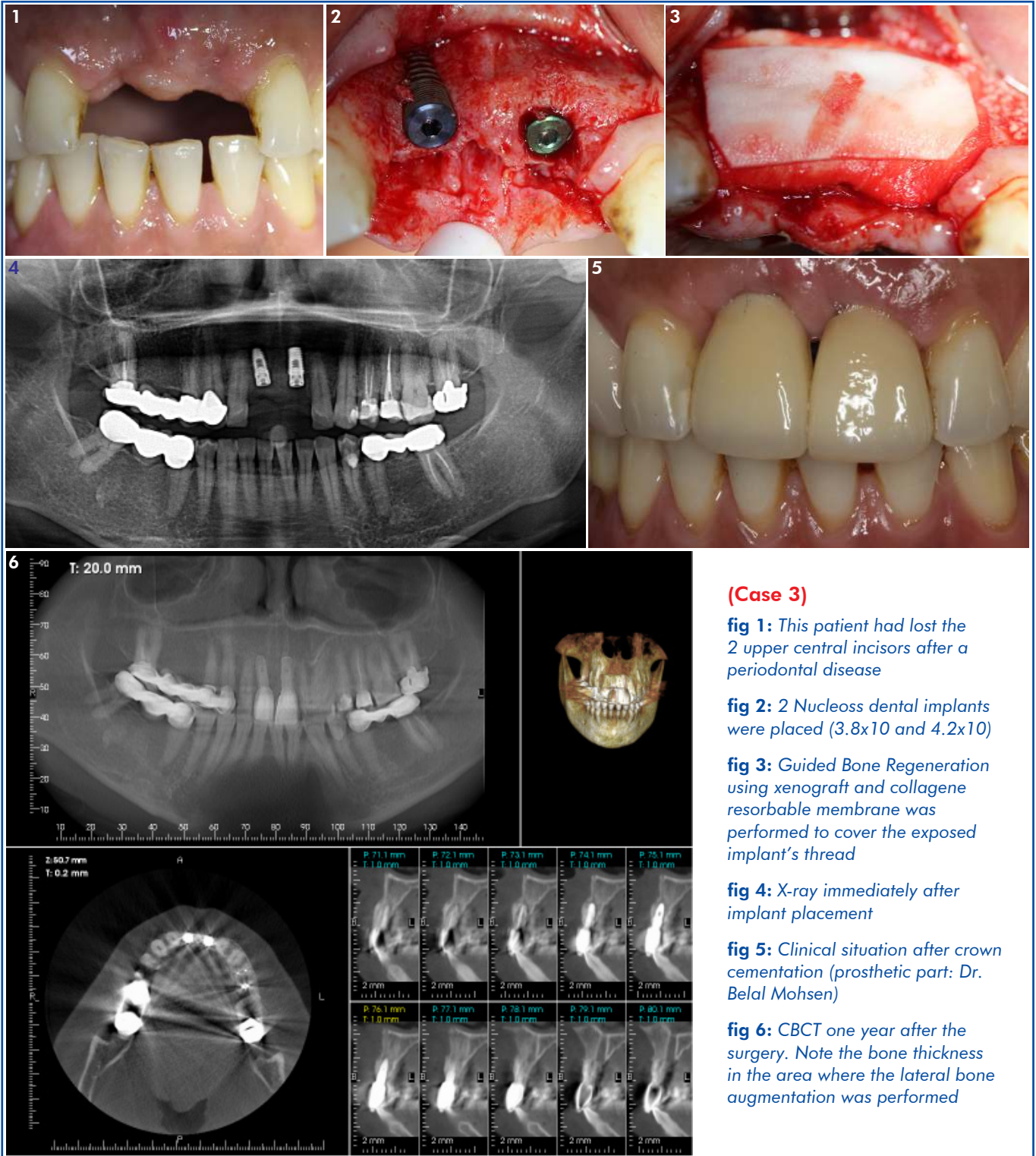
it can also be associated to the survival/success of the dental implants placed on the site as it would ultimately reflect the final outcome. (Chiapasco et al. 2009) Donos et al. (2008) performed a meta-analysis to compare the clinical outcome of implants following lateral bone augmentation procedures. The three studied parameters were GBR, onlay bone graft and split osteotomy, each compared with implants placed in pristine bone (control group). The studies of Mayfield et al. 1998, Zitzmann et al. 2001, Corrente et al. 2000 and Ozkan et al. 2007 were found to be eligible to the meta-analysis. The results showed that the survival rate was not statistically different between the test and control groups: it varied from 91.7% to 100% and from 93.2% to 100% respectively. Table 1 shows the details of each study.

In a retrospective study including 34 patients followed up to 5 years, Benić et al. (2009) compared the survival rate of 34 machined screw-type implants placed in site with simultaneous GBR versus 34 implants placed in pristine bone. The cumulative success rates reached 100% in the GBR group and 94.1% in the control group without any statistical significance. In the control group, two implants were lost; one of them was loaded only 3 weeks after its placement.

It was also observed by Rammelsberg et al. (2012) that the use of several augmentation techniques at the same surgery seems to decrease the implant survival rate. Their retrospective study (4 years, 958 implants) showed a comparatively lower survival rate (94.1%) for the group of implants (n=194) placed in combination with several bone augmentation procedures performed in extensive bone defects. On the other hand, the 304 implants placed in reduced bone width (217 with bone spreading using hand osteotomes, 15 with bone splitting technique and 72 with GBR using autogenous bone chips) had shown 95.8% survival rate. The survival rate of the 372 implants placed in pristine bone (control group) was 97.5%.

For Chiapasco et al. (2009), the majority of studies using the GBR concept for fenestration and dehiscence coverage around implants threads did not evaluate the success rate of implants according to well-defined criteria. Despite these shortcomings, the results of their meta-analysis showed an overall implant's survival rate of 95.7% irrespective of membrane and grafting material.

Bone splitting/expansion seem to be a reliable and relatively noninvasive technique to correct narrow edentulous ridges. Success rates of the surgical procedures ranged from 98% to 100%. Fracture of the buccal plate was the most common complication. Implant survival rates ranged from 91% to 97.3% (median 94%), while success rates ranged from 86.2% to 97.5% (median 95.5%). Survival and success rates of implants placed in the expanded ridges are consistent with those of implants placed in



(Case 3)

fig 1: This patient had lost the 2 upper central incisors after a periodontal disease

fig 2: 2 Nucleoss dental implants were placed (3.8x10 and 4.2x10)

fig 3: Guided Bone Regeneration using xenograft and collagene resorbable membrane was performed to cover the exposed implant's thread

fig 4: X-ray immediately after implant placement

fig 5: Clinical situation after crown cementation (prosthetic part: Dr. Belal Mohsen)

fig 6: CBCT one year after the surgery. Note the bone thickness in the area where the lateral bone augmentation was performed

native, non reconstructed bone. The gap created by sagittal osteotomy/expansion undergoes spontaneous ossification, following a mechanism similar to that occurring in fractures. (Chiapasco et al. 2009; Donos et al. 2008).

Onlay bone graft is also commonly used for horizontal bone reconstruction. The amount of gained bone depends on many factors, among which the residual

ridge, donor sites and host related-factors. Most of studies using onlay bone grafts for three dimensional bone reconstructions had shown good results in terms of graft success as well as implant's survival placed in previously grafted bone, the graft's origin being an important factor for implant survival. (Chiapasco 2009). In a study achieved on 1229 grafts and followed up to 10 years, Khoury et al. (2007) showed an average width gain of 4.8mm.

Studies comparing survival rates - of implant placed following lateral bone augmentation versus implants placed in pristine bone

Author, Year & Study type	Patients Number & Implant Numbers	Type of Procedure & Defect	Lateral Augmentation Technique	Follow-up 1. Control 2. Test	Implant Outcome Augmented Sites 1. Survival 2. Success	Implant at Control/Pristine Post-loading 1. Survival 2. Success	Type of Implants 1. System, design and surface topography (as reported by authors) 2. Diameter and length
Corrente <i>et al.</i> (2000) CCT Split Mouth	29 patients 112 implants	One-stage/ dehiscence, fenestration, intrabony defects 52 implants (29 patients) Vs. 60 implants (29 patients) in pristine sites	Bone substitute Carbonate (Biocoral Gel) fibrin fibronectin	Control: 59 months post-loading (49–82) Test: 55 months post-loading (21–76)	Survival: 91.7% (after removal of early failures) Success: 91.7% (after removal of early failures)	Survival: 93.2% post-loading (after removal of early failures) Success rate: 93.2% post-loading (after removal of early failures)	Screw-vent Paragon 3.75mm
Ozkan <i>et al.</i> (2007) Cohort study	15 patients 35 implants	Two-stage/ autogenous block bone graft 17 Implants (8 patients) Vs. 18 implants (7 patients) in pristine sites	Autogenous mono cortical block particulate chin graft	12 months post-loading	Survival: 100% Success rate: Not mentioned	Survival: 100% Success rate: Not mentioned	SLA Straumann 3.3–4.1 mm (the number of each diameter was not mentioned)
Zitzmann <i>et al.</i> (2001) CCT Split mouth	75 patients 265 implants	One-stage/ fenestration and dehiscence 153 implants (75 patients) Vs. 112 implants (75 patients) in pristine sites	Simultaneous GBR: e-PTFE1 Bio-Oss (24 patients / 41 implants) and Collagen (Bio-Gide) 1 Bio-Oss (75 patients/112 implants)	59.1 months post-loading (range 55–70)	Survival: 95.8% Success rate: Not mentioned	Survival: 97.3% Success rate: Not mentioned	Nobel Biocare Turned surface Diameter: Unclear
Mayfield <i>et al.</i> (1998) CCT Split mouth	7 patients 38 implants	One-stage/ fenestration (11 implants), dehiscence (10 implants) 21 implants (7 patients) Vs. 17 implants (7 patients) in pristine sites	Simultaneous GBR: Copolymer of polyglycolide and polylactide (Resolut)	24 months post-loading	Survival: 100% Success rate: Not mentioned	Survival: 100% Success rate: Not mentioned	Brånemark Turned surface Diameter: Not mentioned
Benić <i>et al.</i> (2009) Cross sectionnal retrospective study Split mouth	34 patients 68 implants	One-stage/ dehiscence and fenestrations, infra bony defects 34 implants (34 patients) Vs. 34 implants (34 patients) in pristine sites	GBR using autogenous bone chips mixed with xenograft – resorbable membrane	60 months post-loading	Survival: 94.1 Success rate: Not mentioned	Survival: 100% Success rate: Not mentioned	Brånemark Turned surface In the control group: 23 RP, 10 WP, 1 NP. Test group: 24 RP, 9WP, 1 NP

DISCUSSION

It has been advocated that the follow-up period for validation of an implant system placed in pristine bone should be at least 5 years (Wennström & Palmer 1999). It could be argued that similar observation periods are needed for implants placed in sites following a lateral augmentation procedure or for narrow-diameter implants.

To answer the question whether both diameters show the same survival/success rate, we need to conduct a randomized controlled study comparing in the same patient narrow-diameter implant versus standard-diameter implant placed with lateral bone augmentation. Since this kind of studies does not exist, our review focused on two types of studies:

1. Studies using narrow diameter implants, sometimes placed simultaneously with local bone augmentation.
2. Studies comparing the survival rate of implants placed in grafted sites versus implants placed in native bone, most of these implants having a standard diameter.

The results show good survival rate for narrow-diameter implants as well as standard-diameter implants placed with lateral bone augmentation.

However, the usefulness of small-diameter implants has to be discussed with an awareness of its potential limitation. Small-diameter implants of 3.0-3.5 compared with regular-size implants are structurally weaker (Comfort et al. 2005). On the other hand, lateral ridge augmentation using different techniques is not free from complications, mainly infection leading to the complete loss or a part of the graft, peri-implant mucosal swelling (Zitzmann et al. 2001; Donos et al. 2008), flap dehiscence as well as patient morbidity.

Most of studies comparing the survival rate of implants placed in pristine bone versus implant placed with lateral bone augmentation were rated as high risk of bias. For example, Ozkan et al. (2007) did not include smokers in their study. Mayfield et al. (1998) included only one smoker out of the total seven patients. In the remaining studies, the smoking habits were unclear. Other weaknesses can also be noticed in almost all the studies, such as the removal of failed implants from the final statistical analysis (Corrente et al. 2000), lack of standardized radiographs (Mayfield et al. 1998; Zitzmann et al. 2001) and the recruitment of a small number of patients. The study of Benić (2009) was retrospective; also patients' inclusion criteria were not specified.

Moreover, and for a safer use of narrow-diameter implants, the practitioner must attribute high significance to the occlusal scheme, biomechanical issues, prostheses type, implants macro and microgeometry, as well as to possible parafunctions.

Implant's macro and microgeometry can also affect the survival rates of implants placed in grafted sites. On the other hand, the success of lateral bone augmentation is related to many other factors, including practitioner learning experience and patient's health status. Such procedures involve patient's financial status, higher cost and an extended treatment time in case of staged approach.

CONCLUSION

The use of narrow-diameter implant as well as lateral bone augmentation are well documented in the literature as a treatment modality in reduced ridge width (Esposito et al. 2008; Chiapasco et al. 2009, 2012; Málo 2011; Vigolo et al. 2004). Each treatment approach has its advantages and downsides. On one hand, narrow-diameter implant is a simple and predictable treatment when used properly. On the other hand, hard tissue management improves implant survival rate together with soft tissue contour and phonetics. Moreover, lateral bone augmentations are sometimes required to optimize the sagittal intermaxillary relationship. (Veltri et al. 2008).

In conclusion of this debate, some reflections can be drawn:

1. Implant macro and micro geometry enhance the outcome of the narrow-diameter implant as well as the outcome of implants placed in grafted sites. (Buser et al. 2004; Chiapasco et al. 2009; Barter et al. 2011).
2. GBR is a well documented technique for the treatment of dehiscence and fenestrations (Saad et al. 2012), whether it is used with narrow- or standard-diameter implants. In terms of morbidity and treatment time, GBR used as a simultaneous approach seems to have many advantages above other techniques of lateral bone augmentation.
3. In class IV of Cawood and Howell (1988), the use of narrow-diameter implant should be seriously considered in all kind of edentulism. In some cases, their use could be enhanced with simultaneous lateral bone augmentation for optimal hard and soft tissue contour. In such a situation, the placement of a standard- or wide-diameter implant is almost preceded with more advanced lateral bone augmentation (onlay block, GBR using non resorbable membrane, etc...)
4. Because of its related morbidity, cost and prolonged treatment time, the use of onlay bone block could be only reserved to extreme horizontal bone resorptions where even a narrow-diameter implant cannot be placed with simultaneous GBR.

- The quality of the biomechanical response to loading remains one essential factor in implant restoration success, regardless of the procedure. Many of the occlusal parameters remain however within the hands of the prosthodontist. (Málo)

REFERENCES

- Adell R, Lekholm, U, Grondahl K, Brånemark, PI, Lindstrom J, Jacobsson M. Reconstruction of severely resorbed edentulous maxillae using osseointegrated fixtures in immediate autogenous bone grafts. *Int J Oral Maxillofac Implants.* 1990;5:233-46.
- Albrektsson T, Zarb G., Worthington P, Eriksson, AR. The long term efficacy of currently used dental implants: a review and proposed criteria of success. *Int J Oral Maxillofac Implants.* 1986;1:1-25.
- Allum SR, Tomlinson RA, Joshi R. The impact of loads on standard-diameter, small-diameter and mini implants: a comparative laboratory study. *Clin Oral Impl Res.* 2008;19:553-9.
- Al-Nawas B, Brägger U, Meijer H, Naert I, Persson R, et al. A double-blind randomized controlled trial (RCT) of titanium-13 zirconium versus titanium grade IV small-diameter bone level implants in edentulous mandibles – Results from a 1-year observation period. *Clinical Implant Dentistry & Related Research.* 2012;14(6):896-904.
- Andersson L, Emami-Kristiansen Z, Hogstrom J. Single-tooth implant treatment in the anterior region of the maxilla for treatment of tooth loss after trauma: a retrospective clinical and interview study. *Dental Traumatology.* 2003;19:126-31.
- Barter S, Stone P, Brägger U. A pilot study to evaluate the success and survival rate of titanium-zirconium implants in partially edentulous patients: results after 24 months of follow-up. *Clin Oral Impl Res.* 2012;23:873-81.
- Benić GI, Jung RE, Siegenthaler DW, Hämmerle CHF. Clinical and radiographic comparison of implants in regenerated or native bone: 5-year results. *Clin Oral Impl Res.* 2009;20:507-13.
- Blanco J, Alonso A, Sanz M. Long-term results and survival rate of implants treated with guided bone regeneration: a 5-year case series prospective study. *Clin Oral Impl Res.* 2005;16:294-301.
- Buser D, Broggin N, Wieland M, Schenk RK, Denzer A.J, Cochran DL, Hoffmann B, Lussi A, Steinemann SG. Enhanced bone apposition to a chemically modified SLA titanium surface. *J Dent Res.* 2004;83:529-33.
- Buser D, Mericske-Stern R, Bernard JP, Behneke A, Behneke N, Hirt HP, Belser UC, Lang NP. Long-term evaluation of nonsubmerged ITI implants. Part 1: 8-year life table analysis of a prospective multi-center study with 2359 implants. *Clin Oral Impl Res.* 1997;8:161-72.
- Cawood JI, Howell RA. A classification of the edentulous jaws. *Int J Oral Maxillofac Surg.* 1988;17(4):232-6.
- Chiapasco M, Ferrini F, Casentini P, Accardi S, Zaniboni M. Dental implants placed in expanded narrow edentulous ridges with the Extension Crest device. A 1-3-year multicenter follow-up study. *Clin Oral Impl Res.* 2006a;17:265-72.
- Chiapasco M, Zaniboni M, Boisco M. Augmentation procedures for the rehabilitation of deficient edentulous ridges with oral implants. *Clin Oral Impl Res.* 2006;17(2):136-59.
- Chiapasco M, Zaniboni M. Clinical outcomes of GBR procedures to correct peri-implant dehiscences and fenestrations: a systematic review. *Clin Oral Impl Res.* 2009;20(4):113-23.
- Chiapasco M, Casentini P, Zaniboni M, Bone augmentation procedures in implant dentistry. *Int J Oral Maxillofac Implants.* 2009;24:237-59.
- Chiapasco M, Casentini P, Zaniboni M, Corsi E, Anello T. Titanium-zirconium alloy narrow-diameter implants (StraumannRoxolid®) for the rehabilitation of horizontally deficient edentulous ridges: prospective study on 18 consecutive patients. *Clin Oral Impl Res.* 2012;23:1136-41.
- Christensen DK, Karoussis IK, Joss A, Hämmerle CH, Lang NP. Simultaneous or staged installation with guided bone augmentation of transmucosal titanium implants. A 3-year prospective cohort study. *Clin Oral Impl Res.* 2003;14:680-6.
- Corrente G, Abundo R, Cardaropoli D, Cardaropoli G, Martuscelli G. Long-term evaluation of osseointegrated implants in regenerated and non-regenerated bone. *Int J Periodontics Restorative Dent.* 2000;20:390-7.
- Cordaro L, Torsello F, Mirisola Di Torresanto V, Rossini C. Retrospective evaluation of mandibular incisor replacement with narrow neck implants. *Clin Oral Impl.* 2006;17(6):730-5.
- Jensen J, Sindet-Pedersen S. Autogenous mandibular bone grafts and osseointegrated implants for reconstruction of the severely atrophied maxilla: a preliminary report. *J Oral Maxillofac Surg.* 1991;49:1277-87.
- Davarpanah M, Martinez H, Tecucianu, JF, Celletti R, Lazzara R. Small-diameter implants: indications and contraindications. *Int J Esthet Dent.* 2000;12:186-94.
- Degidi M, Piattelli A, Carinci F. Clinical outcome of narrow-diameter implants: a retrospective study of 510 implants. *J Periodontol.* 2008;79:49-54.
- Donos N, Mardas N, Chadha V. Clinical outcomes of implants following lateral bone augmentation: systematic assessment of available options (barrier membranes, bone grafts, split osteotomy). *J Clin Periodontol.* 2008;35(8):173-202.
- Esposito M, Grusovin MG, Kwan, S, Worthington HV, Coulthard P. Interventions for replacing missing teeth: bone augmentation techniques for dental implant treatment. *Cochrane Database of Systematic Reviews.* 2008;3:CD003607.
- Flanagan D. Fixed partial dentures and crowns supported by very small diameter dental implants in compromised sites. *Implant Dentistry.* 2008;17:182-91.
- Froum S, Emriaz S, Bloom MJ, Scolnick J, Tarnow DP. The use of transitional implants for immediate fixed temporary prostheses in cases of implant restorations. *Practical Periodontics & Aesthetic Dentistry.* 1998;10:737-46.
- Gottlow J, Dard M, Kjellson F, Obrecht M, Sennerby L. Evaluation of a new titanium-zirconium dental implant: a biomechanical and histological comparative study in the mini pig. *Clinical Implant Dentistry and Related Research.* 2010; doi:10.1111/j.1708-8208.2010.00289.x.
- Hallab NJ, Vermes C, Messina C, Roebuck KA, Glant TT, Jacobs JJ. Concentration- and composition-dependent effects of metal ions on human MG-63 osteoblasts. *J Biomed Mat Res.* 2002;60:420-33.
- Ikarashi Y, Toyoda K, Kobayashi E, Yoneyama T, Hamanaka H, Tsuchiya T. Improved biocompatibility of Titanium-Zirconium (Ti-Zr) alloy: tissue reaction and sensitization to Ti-Zr alloy compared with pure Ti and Zr in rat implantation study. *Mater Trans.* 2005;46:2260-7.
- Khoury F, Khoury C. Mandibular bone block grafts: Diagnosis, instrumentations, harvesting techniques and surgical procedures In: Bone augmentation in oral implantology. Khoury F, Antoun H, Missika P. *Quintessence.* 2007:115-212.
- Málo P, de Araujo Nobre M. Implants (3.3mm diameter) for the rehabilitation of edentulous posterior regions: a retrospective clinical study with up to 11 years of follow-up. *Clinical Implant Dentistry & Related Research.* 2011;13:95-103.
- Mayfield L, Skoglund A, Nobreus N, Attstrom R. Clinical and radiographic evaluation, following delivery of fixed reconstructions, at GBR treated titanium fixtures. *Clin Oral Impl Res.* 1998;9:292-302.
- Mayfield LJ, Skoglund A, Hising P, Lang NP, Attstrom R. Evaluation following functional loading of titanium fixtures placed in ridges augmented by deproteinized bone mineral. A human case study. *Clin Oral Impl Res.* 2001;12:508-14.
- Morneburg T.R, Proschel PA. Success rates of microimplants in edentulous patients with residual ridge resorption. *Int J Oral Maxillofac Implants.* 2008;23:270-6.
- Oates TW, Valderrama P, Bischof M, Nedir R, Jones A, Simpson J, Toutenburg H, Cochran DL. Enhanced implant stability with a chemically modified SLA surface: a randomized pilot study. *Int J Oral Maxillofac Implants.* 2007;22:755-60.
- Olate S, Lyrio M, De Moraes M, Mazzonetto R, Fernandes Moreira R. Influence of diameter and length of implant on early dental implant failure. *Int J Oral Maxillofac Surg.* 2010;68:414-9.
- Ozkan Y, Ozcan M, Varol A, Akoglu B, Ucakale M, Basa S. Resonance frequency analysis assessment of implant stability in labial onlay grafted posterior mandibles: a pilot clinical study. *Int J Oral Maxillofac Implants.* 2007;22:235-42.
- Petrie CS, Williams JL. Comparative evaluation of implant designs: influence of diameter, length, and taper on strains in the alveolar crest. A three-dimensional finite-element analysis. *Clin Oral Impl Res.* 2005;16:486-94.

39. Pikos M, Mandibular block autografts for alveolar ridge augmentation. *Atlas Oral Maxillofacial Surg Clin N Am*. 2005;13:91-107.
40. Qian L, Todo M, Matsushita Y, Koyano K. Effects of implant diameter, insertion depth, and loading angle on stress/strain fields in implant/jawbone systems: finite element analysis. *Int J Oral Maxillofac Implants*. 2009;24:877-886.
41. Quek CE, Tan KB, Nicholls JI. Load fatigue performance of a single-tooth implant abutment system: effect of diameter. *Int J Oral Maxillofac Implants*. 2006;21:929-36.
42. Rammelsberg P, Schmitter M, Gabbert O, Lorenzo Bermejo J, Eiffler C, Schwarz S. Influence of bone augmentation procedures on the short-term prognosis of simultaneously placed implants. *Clin Oral Impl Res*. 2012;23:1232-7.
43. Renouard F, Nisand D. Impact of implant length and diameter on survival rates. *Clin Oral Impl Res*. 2006;17(2):35-51.
44. Romeo E, Lops D, Amorfini L, Chiapasco M, Ghisolfi M, Vogel G. Clinical and radiographic evaluation of small-diameter (3.3mm) implants followed for 1-7 years: a longitudinal study. *Clin Oral Impl Res*. 2006;17:139-48.
45. Saadoun AP, Le Gall MG. An 8-year compilation of clinical results obtained with SteriOss endosseous implants. *Compendium Continue Education Dentistry*. 1996;17:669-74,676 passim; quiz 688.
46. Schwarz MS. Mechanical complications of dental implants. *Clin Oral Impl Res*. 2000;11:(1):156-8.
47. Saad M, Assaf A, Maghaireh H. Guided bone regeneration: Evidences and limits. *Smile Dental Journal*. 2012;7(1):8-16.
48. Sohrabi K, Mushantat A, Esfandiari S, Feine J. How successful are small-diameter implants? A literature review. *Clin Oral Impl Res*. 2012;23:515-25.
49. Thompson GJ, Puleo DA. Ti-6Al-4V ion solution inhibition of osteogenic cell phenotype as a function of differentiation time course *in vitro*. *Biomaterials*. 1996;17:1949-54.
50. Veltri M, Bertelli E, Ferrari M, Balleri P. One-year outcome of narrow-diameter blasted implants for rehabilitation of maxillas with knife-edge resorption. *Clin Oral Impl Res*. 2008;19:1069-73.
51. Vigolo P, Givani A, Majzoub Z, Cordioli G. Clinical evaluation of small-diameter implants in single-tooth and multiple-implant restorations: a 7-year retrospective study. *Int J Oral Maxillofac Implants*. 2004;19:703-9.
52. Wennström J, Palmer R. Consensus report: clinical trials. In: Lang, N. P. & Karring, T. (eds) *Proceedings of the 3rd European Workshop on Periodontology*, Berlin: Quintessence. 1999:255-9.
53. Zinsli B, Sägesser T, Mericske E, Mericske-Stern R. Clinical evaluation of small diameter ITI implants: a prospective study. *Int J Oral Maxillofac Implants*. 2004;19:92-9.
54. Zitzmann NU, Schärer P, Marinello CP. Long-term results of implants treated with guided bone regeneration: a 5-year prospective study. *Int J Oral Maxillofac Implants*. 2001;16:355-66.